



Independent External Validation of Deep Learning-based Echocardiographic Detection of Cardiac Amyloidosis using a Global Multiethnic Population

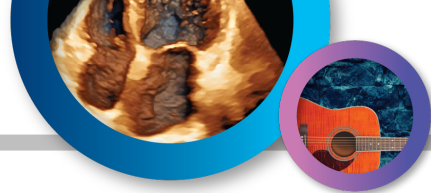Michael J. Randazzo, Jeremy A. Slivnick, Sze Chi Lim, Mathew S. Maurer, Stephen Helmke, Marielle Scherrer-Crosbie, Marwa Soltani, Akash Goyal, Karolina M. Zareba, Richard Cheng, Nicole Nakamatsu, Tetsuji Kitano, Masaaki Takeuchi, Viviane Tiemi Hotta, Marcelo Luiz Campos Vieira, Pablo Elissamburu, Ricardo E. Ronderos, Aldo Prado, Efstratios Koutroumpakis, Anita Deswal, Amit Pursnani, Nitasha Sarswat, Juan Cotella, Amit R. Patel, Karima Addetia, Frederick L. Ruberg, Federico M. Asch, Marianna Fontana, Roberto M. Lang



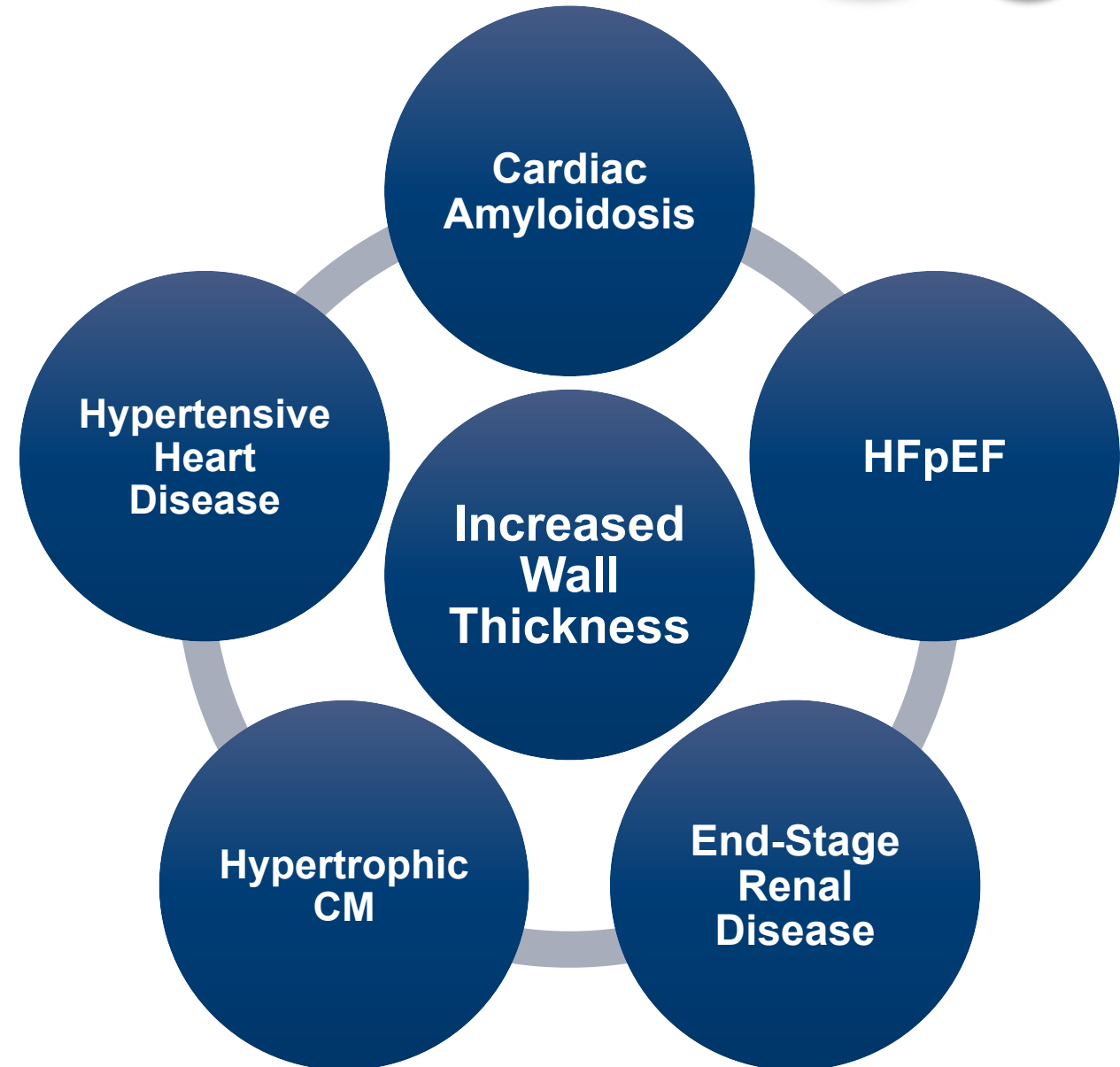
THE UNIVERSITY OF
CHICAGO

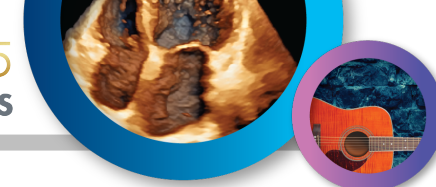UChicago Medicine





- Detection of cardiac amyloidosis (CA) using initial clinical, biomarker, and imaging findings has been limited by overlapping phenotypes with other etiologies of increased wall thickness
- Early identification of CA is critical due to its progressive disease course and the existence of disease-halting therapies
- Echocardiography plays a pivotal role as the first-line imaging modality for any patient with symptoms of heart failure

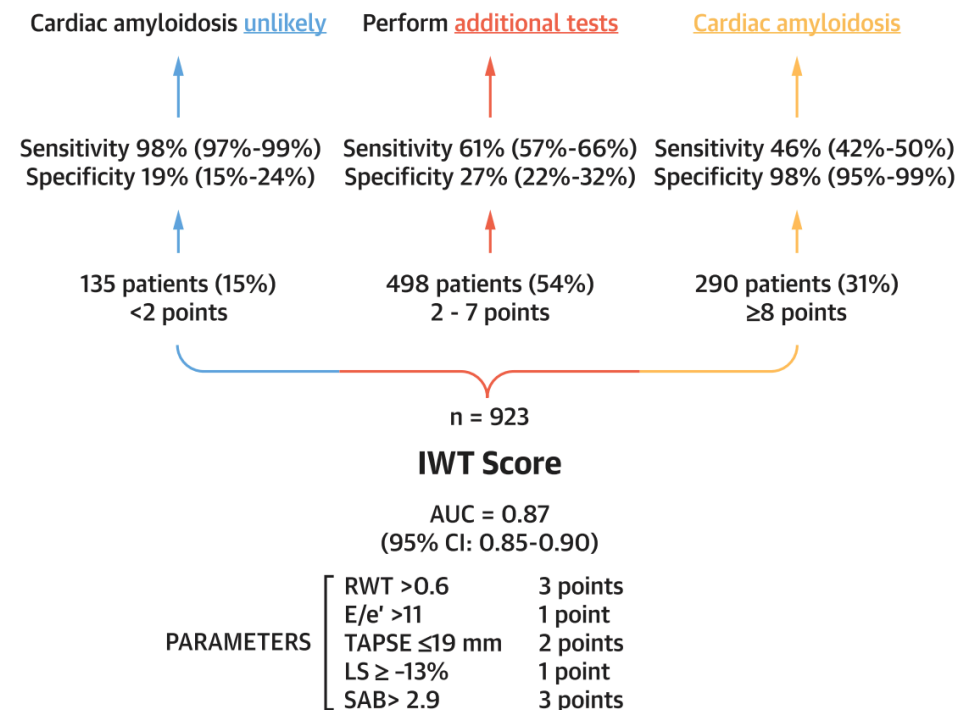




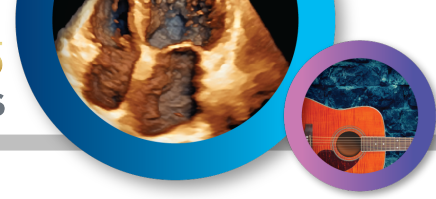Individual Echocardiographic Parameters

	ROC AUC	Optimal cut-off	Sensitivity	Specificity	NPV	PPV	Accuracy
LV EF	0.56	54	0.60	0.48	0.30	0.76	0.55
LV EDVi	0.72	53	0.79	0.61	0.32	0.92	0.74
RWT	0.77	0.57	0.74	0.73	0.51	0.88	0.74
E/A	0.67	1.06	0.68	0.61	0.52	0.74	0.65
E/e'	0.62	18.4	0.38	0.73	0.32	0.80	0.50
LV GLS	0.57	-17.0	0.71	0.42	0.35	0.77	0.64
ASR	0.74	1.67	0.72	0.66	0.50	0.84	0.74
TAPSE	0.69	18.1	0.67	0.62	0.39	0.83	0.64
RV FAC	0.68	33	0.55	0.73	0.34	0.85	0.58
LAS	0.68	11	0.52	0.73	0.34	0.84	0.55
EF/LS	0.55	3.4	0.51	0.59	0.31	0.77	0.56
LVMi/LS	0.56	6.4	0.66	0.50	0.22	0.87	0.66
AMyli	0.74	7.8	0.76	0.65	0.51	0.83	0.73
MCF	0.68	26	0.68	0.65	0.26	0.92	0.68

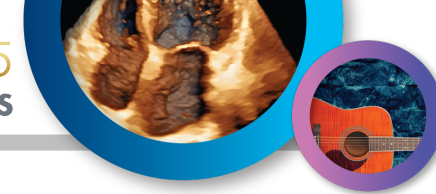
Increased Wall Thickness (IWT) Score



Individual parameters have demonstrated variable discriminatory abilities, while multiparametric scores are time-consuming and infeasible in many patients



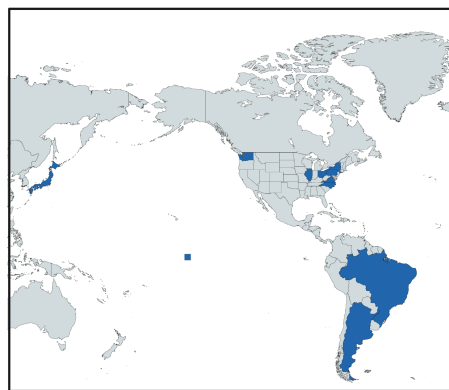
1. Validate the performance of a novel, deep-learning (DL) model to detect cardiac amyloidosis on a single apical four-chamber videoclip across a global, multiethnic population
2. Compare the model's diagnostic performance to established multiparametric echocardiographic scores
3. Assess generalizability of the deep-learning model across amyloid subtypes



Independent Validation Cohort (10 Sites)

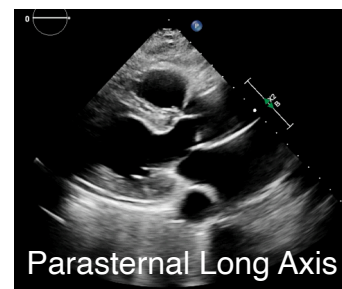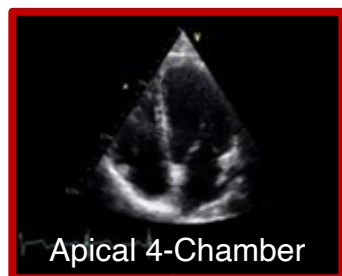Cardiac Amyloid
ATTR-CA (n=432)
AL-CA (n=341)
Other Subtype (n=23)

Controls
Suspected ATTR-CA and negative PyP/Bx (n=229)
AL without cardiac involvement (n=126)

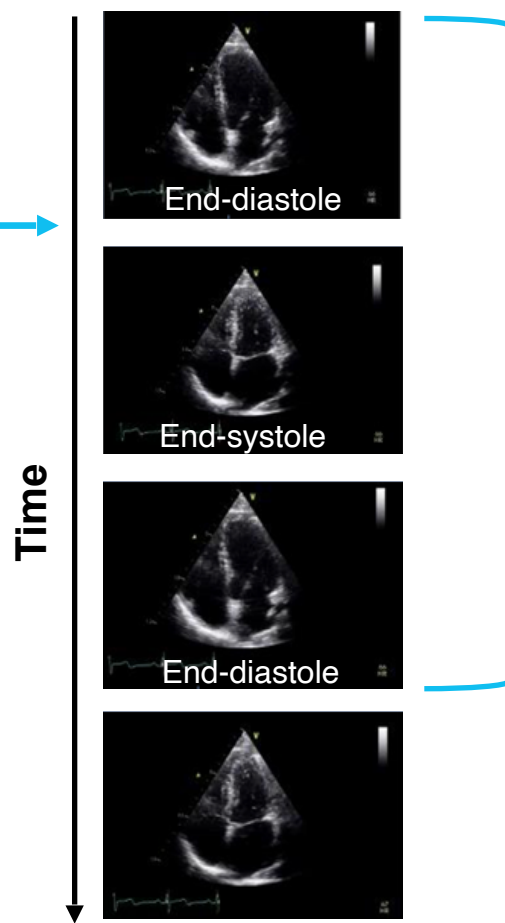


Data Preprocessing

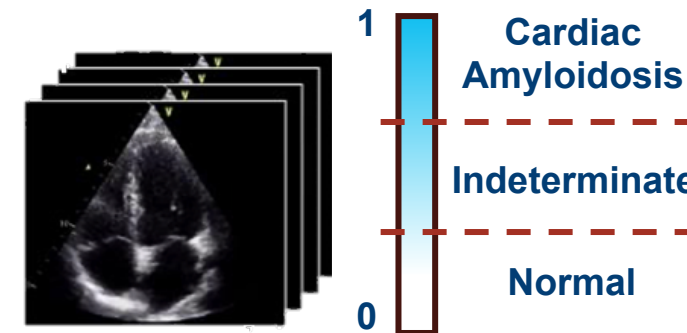
Echocardiographic View Classifier



Phase Detection



Deep-Learning CA Model

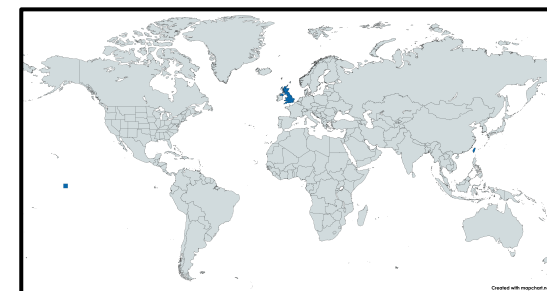


Single Cardiac Cycle

Cardiac Amyloid
ATTR-CA (1,857)
AL-CA (n=384)

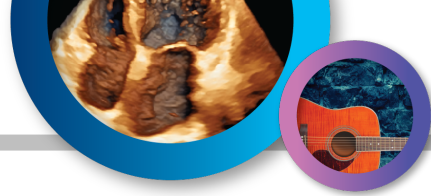Controls
(n=1,526)

Training Cohort (2 Sites)





- **Model Architecture:** A video-based classifier following the small variant of the Multiscale Vision Transformers (MViTv2) architecture
- **Input:** A single cardiac cycle of an apical four-chamber view
- **Output:** A probability score between 0 and 1 indicating the likelihood of cardiac amyloidosis
- **Score Interpretation:**
 - Cardiac amyloidosis: ≥ 0.8
 - Negative: ≤ 0.45
 - Indeterminate: >0.45 and <0.8

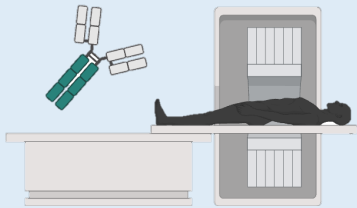


Transthyretin Cardiac Amyloidosis (ATTR-CA)

Endomyocardial biopsy
with ATTR amyloid

OR

Perugini Grade 2 or 3
uptake on 99mTc-DPD
scintigraphy without an
abnormal free light-chain
ratio or monoclonal
gammopathy



Light Chain Cardiac Amyloidosis (AL-CA)

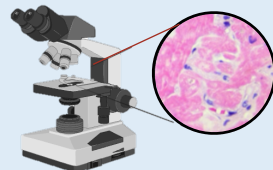
Endomyocardial biopsy
with AL amyloid

OR

Characteristic features on
cardiac magnetic
resonance imaging

AND

Systemic AL amyloidosis
on extra-cardiac biopsy



Suspected Cardiac Amyloidosis: Negative Work-up

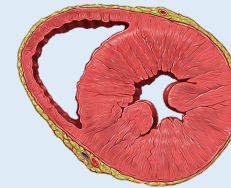Negative endomyocardial
biopsy

OR

Normal light chain analysis

AND

Perugini Grade 0 or 1
uptake on 99mTc-DPD
scintigraphy



Systemic AL Amyloidosis without Cardiac Involvement

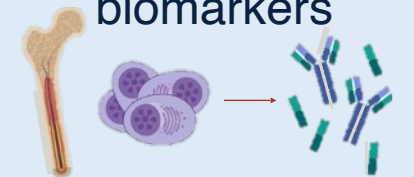
Systemic AL amyloidosis
on extra-cardiac biopsy

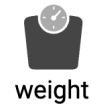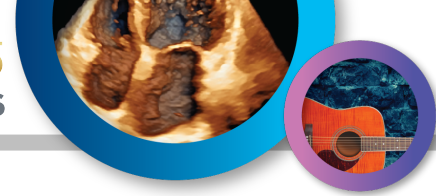AND

Negative endomyocardial
biopsy

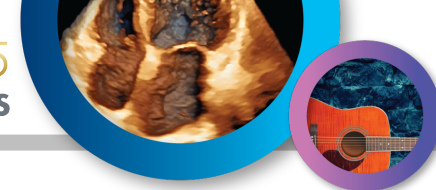
OR

Normal diagnostic
imaging or cardiac
biomarkers

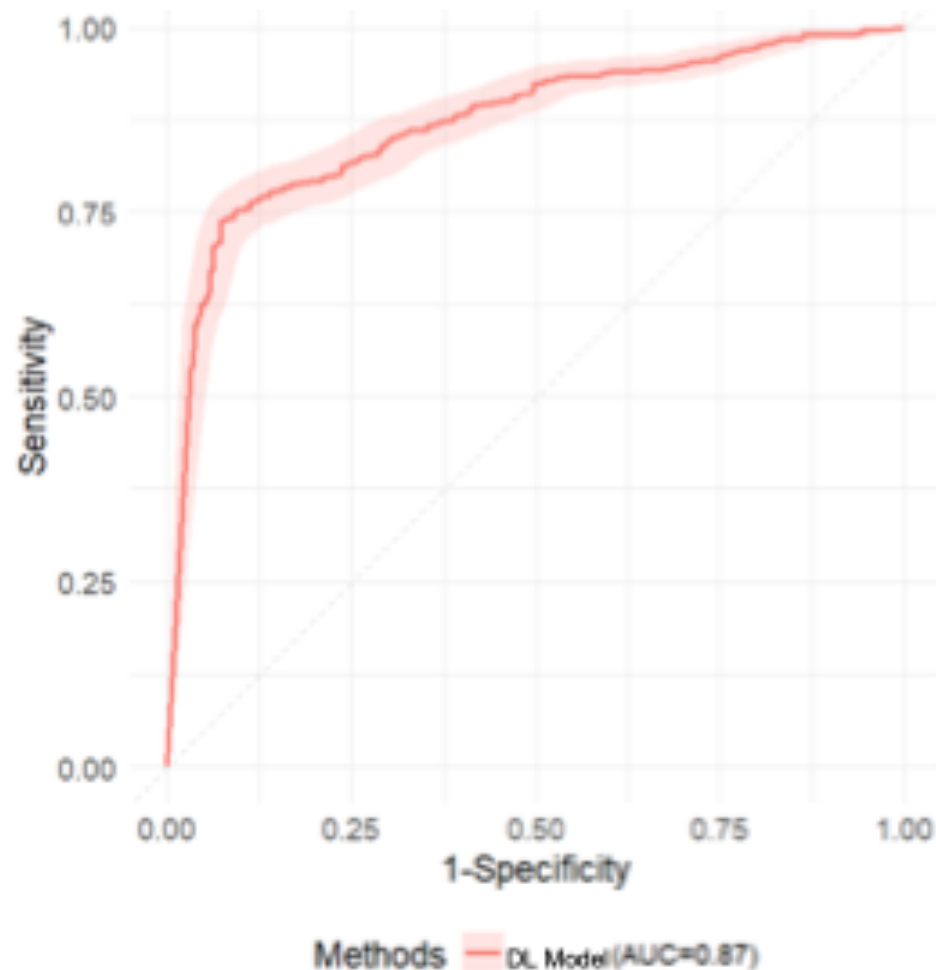




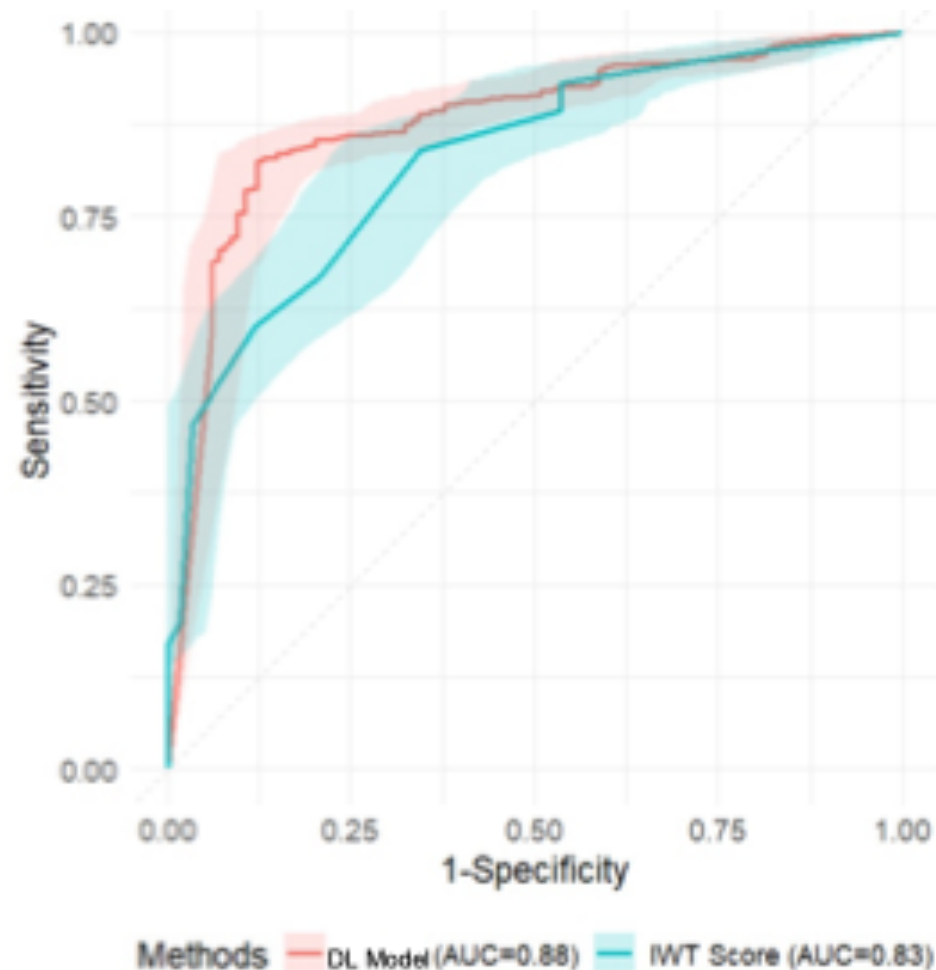
Clinical characteristics	CA (N=720)	Controls (N=311)
Age, years, mean \pm SD	70.9 \pm 11.0	69.3 \pm 13.8
Weight, kg, mean \pm SD	78.4 \pm 19.8	82.5 \pm 22.0
Height, cm, mean \pm SD	170.7 \pm 11.6	169.1 \pm 11.4
BMI, kg/m ² , mean \pm SD	26.8 \pm 6.1	28.9 \pm 7.6
Gender, male, n (%)	531 (73.8%)	179 (57.6%)
Ethnicity, n (%)		
- Black	211 (29.3%)	102 (32.8%)
- Hispanic or Latino	118 (16.4%)	19 (6.1%)
- White	279 (38.8%)	162 (52.1%)
- Other/ Not reported	112 (15.6%)	28 (9.0%)
NT-proBNP, pg/ml, median (IQR)	2,492 (710-6,542)	813 (182-3,804)
BNP, pg/ml, median (IQR)	514.0 (240.0-931.0)	87.0 (41.0-280.9)
Creatinine, mg/dL, median (IQR)	1.22 (0.95-1.69)	1.14 (0.88-1.82)
eGFR, mL/min/1.73m ² , median (IQR)	56.3 (36.9-72.0)	59.0 (34.0-80.0)
Echocardiographic Parameters		
RWT, mean \pm SD	0.7 \pm 0.2	0.5 \pm 0.1
TAPSE, mm, mean \pm SD	17.8 \pm 4.9	21.8 \pm 5.2
E/e' Mean, mean \pm SD	17.0 \pm 6.5	12.6 \pm 6.0
A4C LV GLS, %, mean \pm SD	-13.9 \pm 5.1	-16.2 \pm 5.1
A4C LV SAB, mean \pm SD	2.2 \pm 1.1	1.5 \pm 0.7
LV SAB, mean \pm SD	2.2 \pm 1.0	1.4 \pm 0.5



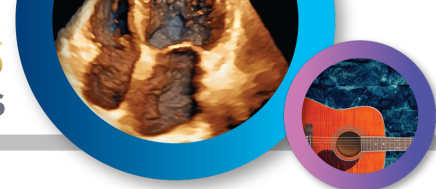All Cardiac Amyloidosis



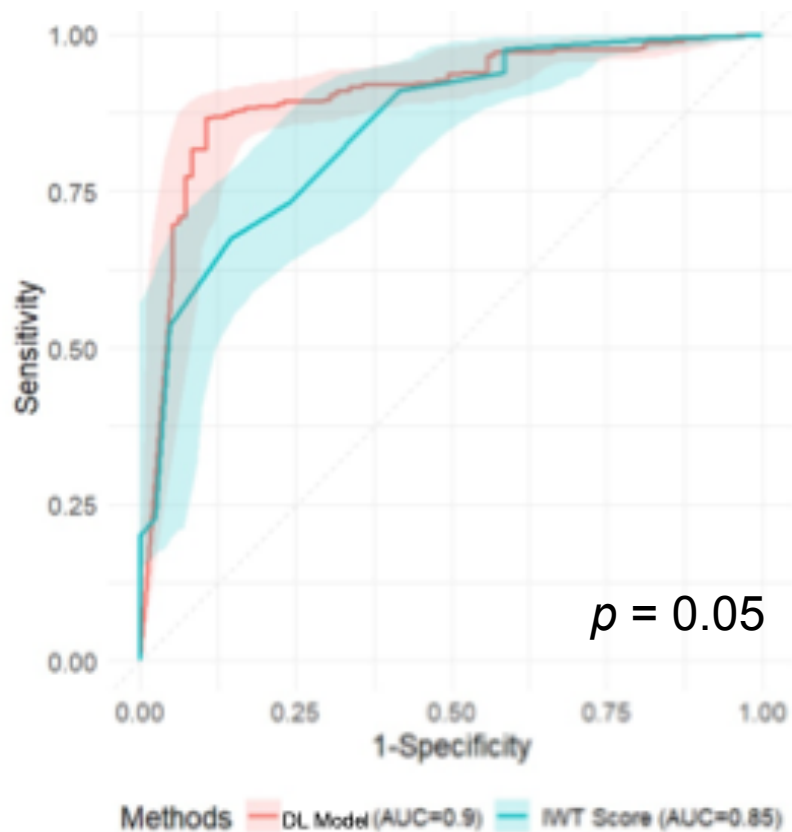
Increased Wall Thickness



DL model achieved excellent discrimination with AUC 0.87, 93% specificity, 74% sensitivity, 80% accuracy, and 89% feasibility



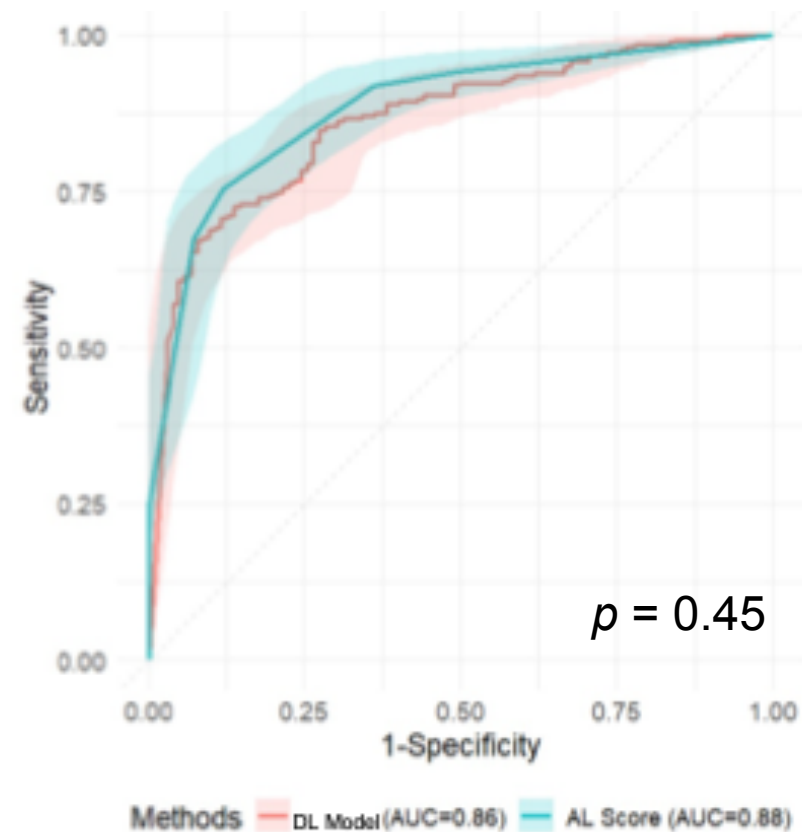
Transthyretin CA (ATTR-CA)



Feasibility: DL Model: 91% IWT Score: 47%

DL model outperformed the IWT Score in detecting ATTR-CA

Light-Chain CA (AL-CA)

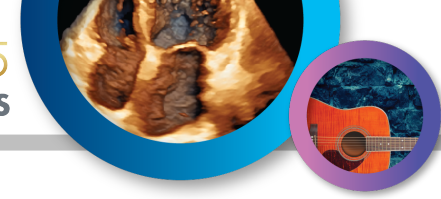

DL Model: 86% IWT Score: 55%

DL model and Systemic AL Score exhibited similar performance, although feasibility of DL model was significantly higher



- **In a diverse cohort, the DL model displayed excellent differentiation of CA among patients with clinical suspicion of disease**
- **The DL model demonstrates high feasibility and provides a rapid, automated assessment**
- **Diagnostic performance is similar across amyloid subtypes**
- **Detection of CA is equivalent or superior to multiparametric echocardiographic scores without requiring cumbersome calculations**



Thank you

Michael Randazzo, MD

Michael.Randazzo@pennmedicine.upenn.edu